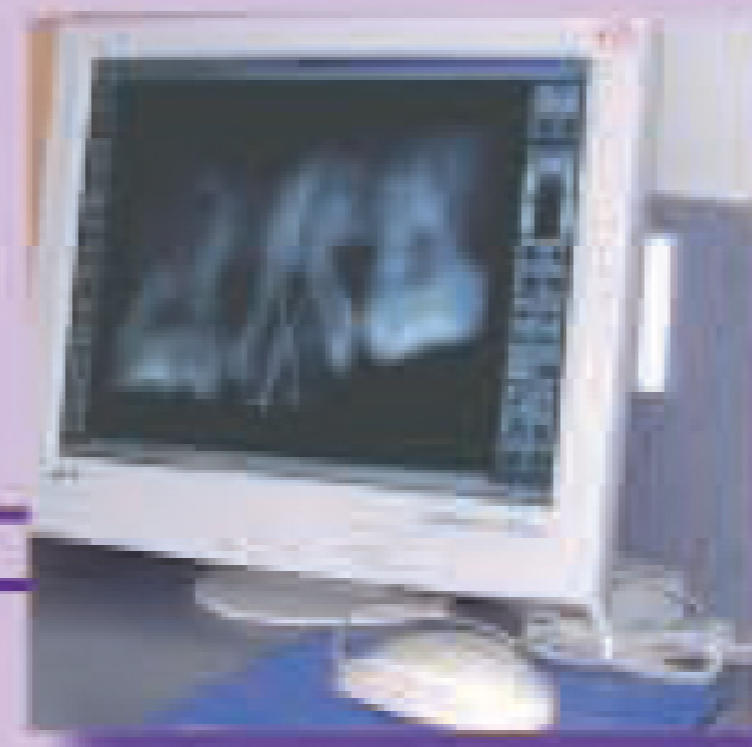


最新消息

於本診所服務了四年多的楊安妮姑娘，已於2006年5月離職，現在在藥劑事業發展。她的離任雖然令我們都很傷感，但我們非常高興有梁玉珮姑娘的加入，並成為行政助理。梁姑娘聯同李姑娘及黃姑娘分擔診所的前線工作外，亦會協助安排預約、資料輸入及會計等事務。

我們其中一位牙科護士，危芷君姑娘亦於8月離職，她在我們診所內是眾所周知一位很好的姑娘。自她離職後，我們聘任了擁有5年牙科護士經驗的林詠儀姑娘，以她獨特的個性及特質，不多久便成為我們團隊的一份子。

我們歡迎梁姑娘和林姑娘的加入！



Dr. William Cheung & Associates

D e n t a l S u r g e o n s

Address: 503 Aon China Building, 29 Queen's Road, Central, Hong Kong SAR.
Tel: 2522-5752, 2522-5979 Fax: 2530-5618 Email: dentist@dentalmirror.com.hk

STAMP





THE DENTAL MIRROR

NEWS FLASH

By Dr. Ellen Yiu

Bad Teeth and Heart Attack

Elderly persons with active root caries have an increased risk of having irregular heartbeats. A new study published in the Journal of the American Geriatrics Society, researchers discovered that persons with 3 or more root caries had more than twice the odds of cardiac arrhythmias than those without. Since arrhythmias can signify other possibly undiagnosed diseases in older people, researchers stress the importance of taking dental diseases seriously and further indicate that root caries may be a marker of general physical decline in the elderly.



And remember... Bad Breath Could be the Result of a Dental Problem

About 85% of people with persistent bad breath have a dental condition that is to blame. If bad breath is the cause of a dental condition, mouthwash will only mask the odor and not cure it. Don't be embarrassed to talk to us, we are here to help you. Flossing daily and brushing your teeth and tongue twice a day can greatly reduce and possibly eliminate bad breath.

消息速遞

資料由姚靄安醫生提供

壞牙與心臟病

長者們患有活躍性牙齦齦的話，會增加心跳不正常的風險。根據在美國老年醫學會期刊刊登的研究顯示，研究人員發現患有三隻或以上活躍性牙齦齦的人，較沒有患此症狀而有心律不正常的人高出兩倍。由於心律不正常可以是來自其他未經診斷的長者病患所致，研究人員著重牙科病的嚴重性，而進一步顯示牙齦齦病患可能是導致長者身體機能減弱的原因。

請緊記，口臭可能是牙齒問題

大概八成半持續有口臭的人都歸咎於牙齒的問題，如果口臭的原因是牙齒的問題所致，漱口只是治標而非治本的方法。不要怕尷尬，講給我們知，我們會幫你解決的！每日使用牙線、刷牙及_刮兩次就能大大減少甚至消除口臭的了！



THE DENTAL MIRROR

最新消息


於本診所服務了四年多的楊安妮姑娘，已於2006年5月離職，現在在藥劑事業發展。她的離任雖然令我們都很傷感，但我們非常高興有梁玉珮姑娘的加入，並成為行政助理。梁姑娘聯同李姑娘及黃姑娘分擔診所的前線工作外，亦會協助安排預約、資料輸入及會計等事務。

我們其中一位牙科護士，危芷君姑娘亦於8月離職，她在我們診所內是眾所周知一位很好的姑娘。自她離職後，我們聘任了擁有5年牙科護士經驗的林詠儀姑娘，以她獨特的個性及特質，不多久便成為我們團隊的一份子。

我們歡迎梁姑娘和林姑娘的加入！



Dr. William Cheung & Associates
Dental Surgeons
Address: 503 Aon China Building, 29 Queen's Road, Central, Hong Kong SAR.
Tel: 2522-5752, 2522-5979 Fax: 2530-5618 Email: dentist@dentalmirror.com.hk



THE DENTAL MIRROR

Dr. William Cheung & Associates
Dental Surgeons

Address: 503 Aon China Building, 29 Queen's Road, Central, Hong Kong SAR. Tel: 2522-5752, 2522-5979 Fax: 2530-5618 Email: dentist@dentalmirror.com.hk

Christmas Newsletter 2006

I graduated from dental school in 1981 so this year marks my 25th year of practicing Dentistry as a profession of which I am very proud and deeply passionate!

As I reflect on the development of Dentistry over the past quarter of a century, I see significant progress in many areas related to the prevention and treatment of oral diseases as well as technological advances in the dental office.

Root canal treatment, for example, has become a very predictable treatment modality as a result of new technique and equipment so that most severely decayed and traumatized teeth can be restored and preserved.

When teeth need to be extracted, we now can resort to implant replacement with a high rate of success provided that treatment is planned carefully and surgical and restorative procedures are carried out properly.

In the area of esthetics we now can offer a variety of procedures to achieve optimum esthetic outcome for those who desire a better looking smile. These include teeth whitening, bonding, porcelain veneers, all-porcelain crowns and even all-porcelain bridges.

The prevention and treatment of gum disease have been a primary focus in Dentistry for a long time. As we already have a thorough understanding of the cause and progression of gum disease and its prevention, we now look for ways to regenerate the loss of bone attachment around teeth and under soft tissues through tissue engineering and bone regeneration techniques. Research in this area is being pursued actively and preliminary results are promising. There is also increasing knowledge about the relationship between oral health and systemic health.

In the technology front, we not only can manage data base, accounts and other administrative tasks with the use of computers, technology also can assist in diagnosis and treatment of disease. I am referring to advanced equipment like the intra-oral camera, digital X-ray, CT scan, surgical microscope, simulation software for guided surgery, to name just a few.

I am thankful that I have witnessed these exciting developments in Dentistry. I am also proud that we are able to offer you the most updated equipment and treatment. My colleagues and I look forward to serving you the best we can in the years to come. On behalf of every member of our team, I wish you a blessed Christmas and a healthy New Year!

Dr. William Cheung

2006 聖誕通訊

自1981年牙科畢業後，我從事一個我非常熱愛又令我倍感驕傲的牙醫行業，今年是我執業的第25年了！當我回顧到近這二十五年來牙醫學界的發展，經歷到在多個相關領域裡有重大的改進，特別是有關預防及治療口腔疾病，與及在牙科診所裡科技上的改良等等。

以牙齦管治療為例，在嶄新的儀器及技術協助下，令大多數的蛀牙及受損傷的牙齒，能在可預測的治療模式下得以修復及保存。

而當有需要拔牙時，現在可以精心地計劃精確的修復程序，提供成功率非常高的植牙服務。

在牙齒美容方面，為了讓您擁有更亮麗的笑容，我們目前可以給您多樣化的步驟去實現最理想最優美的效果。它們包括牙齒漂白、牙齒黏合、瓷片、全瓷牙冠，甚至全瓷牙橋等等。

牙醫學多年來，集中預防及治療牙周病。而隨著我們已經徹底明白牙周病的成因以及預防的方法，此刻我們期待有新的方法，令失去的骨質藉由基因工程再生技術，在骨骼軟體組織下，及牙齒的周邊注入牙髓。就這方面的研究，現已積極地進行，並初步得到正面的結果。此外在口腔健康與全身健康的密切關係方面，亦增強了不少認識。

科技當前，我們不單可以利用電腦操縱資料庫，完成會計及其他行政方面的工作，它更可幫助診斷及治療疾病。我所指的是其中幾種先進儀器，例如口腔內照相機、數碼 X光、電腦斷層掃描器、手術用的顯微鏡、為手術做指導的模擬軟件等等。

我很欣慰能見證現時牙科的發展，亦非常自豪本診所能夠提供大部份最現代化的儀器及治療方法。我與我的員工，期望在未來為您提供最佳的服務。謹代表本診所的每位員工，祝您聖誕快樂，及來年身體健康！

張偉民醫生



Photo taken at Dr William Cheung's lecture during the FDI World Dental Congress in Shenzhen, China. (September 2006)
攝於2006年9月中國深圳世界牙科聯盟年會張偉民醫生之講座

OFFICE UPDATE

After working here for more than four years, Agnes Yeung has resigned in May 2006 to pursue a career in the pharmaceutical industry. Although we were sad to see her leave, we were happy Penny Leung has joined our team as an Administrative Assistant. She shares the front office with May and Vivian and helps in scheduling appointments, data entry and accounts. Penny is friendly and helpful and we are glad to have her in our office.

One of our dental nurses, Ivy also resigned in August 2006. She is a wonderful individual who is well-liked in the office. Since her departure, we recruited Alice Lam who has more than 5 years of experience as a dental nurse. With Alice's special personality and experience, she is well-integrated into the team in no time.

We welcome Penny and Alice as members of our team!

